



PATIENT

Buddy Sullivan

SPECIES

Canine

BREED

Beagle

SEX

Male Neutered

AGE

13 years

WEIGHT

26lbs

INTERPRETED BY

Maggie Machen Lamy,
DVM, DACVIM
(Cardiology)

IMAGING PERFORMED BY

Kelly Vazquez, CVT

HOSPITAL NAME

Ho Ho Kus Veterinary
Hospital

REFERRING VET

Dr. Gannon

PRESENTING CLINICAL SIGNS

History: Recheck echo. Cough. Grade 4/6 murmur.
-Current medications: Doxycycline and Hydrocodone.
-Abnormal PE/Chem/CBC/UA Results: U/A: 2+ protein, UPC 1.5, USG 1.024.
-Pertinent previous echo findings (10/2020 MML): Mild MR, no LA or LVE. LA: 2.0, LV: 3.3.

ECHOCARDIOGRAM FINDINGS

2D, m-mode, color flow and doppler imaging is available. Diffuse thickening of mitral valve leaflets (anterior>posterior) with mild prolapse into the left atrial lumen. Moderate eccentric mitral regurgitation with moderate left atrial dilation. Normal MR velocity. Mildly increased LV diameter with hyperdynamic myocardial function. The tricuspid valve appears mildly thickened with mild tricuspid regurgitation. Normal right atrial and ventricular diameter. The pulmonic and aortic valves are normal in morphology and mobility. Normal pulmonic and aortic outflow velocities. Mild aortic and pulmonic insufficiency. No pericardial or pleural effusion noted. No cardiac tumors observed.

CARDIAC CHART

CANINE CARDIAC PARAMETERS	MR VMAX (m/s)	TR VMAX (m/s)	LA/AO (Boon method)	LA/AO (Heart Base; Swe)	FS (%)	EF (%)	EPSS (cm)
NORMAL PARAMETER	4.5-5.5	<2.7	1.3	<1.6	28-40	40-100	<0.6
PATIENT	6.0	NM	1.4	1.8	30	59	0.3
CANINE CARDIAC PARAMETERS	HR (BPM)	AV VMAX (m/s)	PV MAX (m/s)	BODY WEIGHT (kg)	LA 2D short axis Base view (cm)	LVIDd Avg: 2D and m-mode short axis (cm)	LVIDs Avg: 2D and m-mode short axis (cm)
NORMAL PARAMETER	50-100	0.7-1.7	0.7-1.6	BELOW	BELOW	BELOW	BELOW
PATIENT	80	1.4	1.3	11.8	2.7	3.9	1.8
*Normal chamber parameters expressed as a mean value (SD)				3	1.27 (5.3)	2.46 (2.46)	1.36 (5.5)
BODY WEIGHT DEPENDENT PARAMETERS				5	1.40 (4.5)	2.74 (5.2)	1.60 (4.7)
<i>*Note: All measurements based upon multi-modal images and methods. An average value is reported.</i>				10	1.50 (3.8)	3.27 (3.5)	2.06 (3.1)
				15	1.83 (2.0)	3.71 (2.4)	2.43 (2.1)
				20	2.02 (1.9)	4.14 (2.2)	2.80 (2.0)
				25	2.18 (2.4)	4.48 (2.9)	3.10 (2.5)
				30	2.33 (3.3)	4.83 (3.9)	3.39 (3.4)
				35	2.48 (4.3)	5.17 (5.0)	3.69 (4.5)
				40	2.62 (5.2)	5.48 (6.1)	3.96 (5.4)
				50	2.88 (7.1)	6.07 (8.3)	4.46 (7.4)

INTERPRETATION OF THE FINDINGS & FURTHER RECOMMENDATIONS

Chronic degenerative valve disease persists with evidence of progression. Previously mild disease has become moderate with increasing left heart dimensions. A small tricuspid leak is noted, and the aortic leak is more significant. No additional issues are identified.

INVOICE

24770

DATE

6/14/22

Given these findings, Pimobendan is recommended in this patient as below. A baseline blood pressure is strongly recommended in any animal with AI as well as a history of proteinuria. Assessment of progression in the future will help predict long term outcome, however prognosis is guarded at this stage (B2).



PATIENT

Buddy Sullivan

While mainstem bronchi compression may certainly be contributing to a chronic increase in coughing, other primary airway contributions should also be considered (tracheal collapse, COPD/chronic bronchitis, etc.). Consider hydrocodone for any mechanical component due to cardiomegaly. Screening chest radiographs are recommended.

SPECIES

Canine

Omega fatty acid supplementation and mild salt restriction may also be of some long-term benefit. Monitor for development of a progressive cough, labored breathing, exercise intolerance or collapse episodes.

BREED

Beagle

Once on the medication for 3-5 days, anesthetic risk is considered mildly elevated. Cardiac protective drug choices (opioid/benzodiazepine premedication, Propofol or alfaxalone induction, iso or sevo gas) are recommended. Monitor for arrhythmias, hypotension, and hypoxia both intra and post-operatively and intervene as necessary. Judicious IV fluid rates are recommended to avoid fluid overload. Avoid heart rate stimulating drugs such as atropine unless clinically indicated.

SEX

Male Neutered

AGE

13 years

PLAN

Baseline BP as discussed. Institute heart muscle support Pimobendan 0.3mg/kg PO q12h. Consider hydrocodone as discussed.

WEIGHT

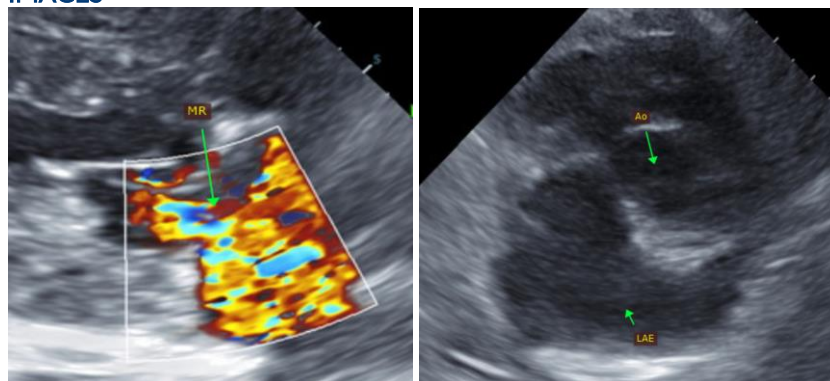
26lbs

Recommend monitor for progression with a recheck echocardiogram in 6 months, sooner if any development of clinical signs.

INTERPRETED BY

Maggie Machen Lamy,
DVM, DACVIM
(Cardiology)

IMAGES



IMAGING PERFORMED BY

Kelly Vazquez, CVT

HOSPITAL NAME

Ho Ho Kus Veterinary
Hospital

REFERRING VET

Dr. Gannon

The information and recommendations provided are based on the images presented by the referring veterinarian. No evaluation can be communicated regarding pathology that was not visible in the image/video clips provided.

INVOICE

24770

Thank you for this referral. This report was generated using transcription software, and minor dictation errors may be present. If the clinical or image interpretation does not parallel your findings or if I can be of any further assistance, please contact me.

DATE

6/14/22

Maggie Machen Lamy, DVM
Diplomate of the American College of Veterinary Internal Medicine (Cardiology)
info@sonopath.com